

# The potential role of Trans-Resveratrol/Carboxymethylated (1.3/1.6)- $\beta$ -d-Glucan minimizing symptoms and improve healing after functional endoscopic sinus surgery

V. FRARI<sup>1</sup>, F. CAPUANO<sup>1</sup>, A. MICERA<sup>2</sup>, F. GRECO<sup>1</sup>, F. SALVINELLI<sup>1</sup>

<sup>1</sup>ENT Department, Campus Biomedico University, Rome, Italy

<sup>2</sup>BioMolecular and Cellular Laboratory, IRCCS Fondazione Bietti, Rome, Italy

**Abstract.** – **OBJECTIVE:** This study aims to evaluate the effect of Trans-Resveratrol/Carboxymethylated (1.3/1.6)- $\beta$ -d-Glucan administered via nasal, after FESS, assessing nasal respiratory distress and nasal mucosa healing.

**PATIENTS AND METHODS:** We enrolled 70 patients, from March 2019 to February 2020, with chronic nasal obstruction not responding to medical therapy and candidates to endoscopic nasal surgery. Patients were divided in two non-randomized groups: group A treated with Trans-Resveratrol/Carboxymethylated (1.3/1.6)- $\beta$ -d-Glucan administered via nasal, and group B treated with 0.9% nasal irrigation saline. Patients were clinically evaluated, in post-operative period, at 7 (T0), 15 (T1), and 30 days (T2) with fibroendoscopy. The CRS (chronic rhinosinusitis) questionnaire (Snot 20) was administered at T0, T1, and T2. The findings were scored with respect to middle turbinate edema. In both Groups, the inferior turbinate's medial aspect was scraped using a sterile disposable Rhino-probe mucosal curette (Arlington Scientific, Inc., Springville, UT, USA) at T0, T1, and T2.

**RESULTS:** Group A showed an improvement in Snot 20 in T1 and T2 both. The reduction of the mucosal edema and nasal secretion has been statistically significant in the Group A. A slight cell reduction was observed at T2 with respect to T1. This decreased pattern is more evident in nasal scraping from Group A. The appearance of epithelial cells at T2 of Group A is consistent with the reduction of inflammatory cells.

**CONCLUSIONS:** We can assert that in Group A it appears less evident the presence of edema, nasal congestion and crusts, resulting in a quick recover.

*Key Words:*

Resveratrol, Functional endoscopic sinus surgery, Nasal spray.

## Introduction

Resveratrol is a polyphenol produced by vegetables and fruit, especially grapes<sup>1,2</sup>. It has been found to exert several activities such as cardioprotective<sup>3</sup>, neuroprotective<sup>4</sup>, anticarcinogenic<sup>5</sup>, antiviral<sup>6</sup>, and anti-inflammatory<sup>7</sup>. It has been found to regulate secretion and inflammation in nasal epithelium also<sup>8</sup>. The nasal epithelium is greatly responsive to autologous and heterologous stimuli and seems to be implicated in several activities, as many paper assessed<sup>9,10</sup>. It has been recently demonstrated that resveratrol can be stabilized in aqueous solutions when combined with a modified  $\beta$ -glucan; this produces a carboxymethylated-(1,3/1,6)- $\beta$ -d-glucan (CM-glucan), which greatly improves the stability of resveratrol in solution without altering its biological activity<sup>11,12</sup>. Resveratrol was studied both *in vitro* and *in vivo*<sup>8</sup> (on murine models). In this study<sup>8</sup>, authors' findings indicate that resveratrol is both a potent CI-secretagogue and anti-inflammatory agent.

Functional endoscopic sinus surgery (FESS) is the treatment of choice for patients with medically resistant chronic rhino-sinusitis (CRS) and nasal polyps. Despite the consolidated use of different treatments, the post-operative period is often very painful and uncomfortable, especially during the first month. The best treatment during this period is still on debate. Studies advocate the use of sterile saline solutions<sup>13</sup>, hypertonic and Ringer solution<sup>14</sup>, sodium hyaluronate<sup>15</sup>

This study aims to evaluate the effect of Trans-Resveratrol/Carboxymethylated (1.3/1.6)- $\beta$ -d-Glucan administered *via* nasal, after FESS, assessing nasal respiratory distress and nasal mucosa healing.

## Patients and Methods

We enrolled 70 patients (mean age 45 years, age range 22-55 years), from March 2019 to February 2020, with chronic nasal obstruction not responding to medical therapy and candidate to endoscopic nasal surgery. All patients had undergone bilateral FESS, involving conservative mucosa-sparing antrostomy, and anteroposterior ethmoidectomy with preservation of the middle turbinate. Frontal and sphenoid sinuses were drained when needed. We excluded patients with nasal polyposis, ongoing pregnancy, nosebleeds, patients immunocompromised, patients who had used antibiotics in the previous 30 days, patients who chronically use immunosuppressive/corticosteroid, and patients with moderate OSAS (Obstructive Sleep Apnea Syndrome).

All patients underwent medical history collection and ear, nose and throat complete examination. The endoscopic nasal examination was carried out with 0.4 mm rigid endoscope (Karl Storz SE & Co. KG, Tuttlingen, Germany) and the questionnaire was administrated (Snot 20). Patients were divided in two non-randomized group. In both groups were administered oral antibiotics (cephalosporins) after surgery twice a day for 5 days.

Group A was treated with 0.9% nasal irrigation saline for the first post-operative week after the removal of the nasal swab. At the second post-operative week, patients add Trans-Resveratrol/Carboxymethylated (1.3/1.6)- $\beta$ -d-Glucan nasal spray 30 ml 1 puff for nostril three times per day for a month.

Group B was treated with 0.9% nasal irrigation saline for the first post-operative week after the removal of the nasal swab. At the second post-operative week, patients continued with 0.9% nasal irrigation saline for a month.

Patients were clinically evaluated, in the post-operative period, at 7 (T0), 15 (T1), and 30 days (T2) after the removal of the nasal swab with fibroendoscopy. The CRS questionnaire (Snot 20) was administrated at T0, T1, and T2.

Endoscopic nasal examination was performed by a flexible nasal fibroendoscopy (Karl Storz SE & Co. KG, Tuttlingen, Germany). The findings were scored with respect to middle turbinate edema (0 none, 1 mild, 2 moderate, and 3 severe) and nasal secretions (0 none, 1 severe).

In both Groups, the inferior turbinate's medial aspect was scraped using a sterile disposable Rhino-probe mucosal curette (Arlington

Scientific, Inc., Springville, UT, USA) at T0, T1, and T2. The same procedures are performed on the left nostril. The collected material was smeared onto glass slide and post fixed with citofix spray (Biolab, Naples, Italy). Biosamples (smear on glass-slide and extract) were preserved according to a standard procedure: slides were stored at 4°C. Slides were stained according to the quick May-Grunwald Giemsa (MGG) procedure (a quick differential staining method). Images were digitally acquired with light transmission by using a direct microscope. Acquisitions were performed the same day of staining/mounting to avoid post preservation and/or fixation artifacts.

The study protocol was approved by the research Ethics Committee at our institution, and every patient signed the written informed consent.

Parametric (Student's *t*-test) was used to compare different values. Our criterion for statistical significance was set at a value of  $p < 0.000001$ . For Snot evaluation, the collected data were expressed as mean and SD (standard deviation).

## Results

### Snot Evaluation

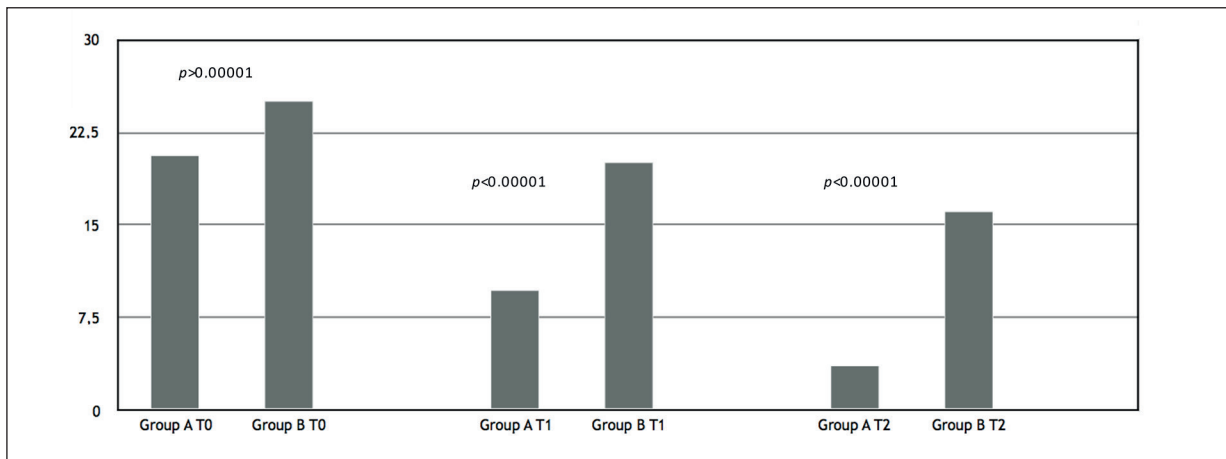
Group A showed an improvement in Snot 20 in T1 and T2 both; nasal respiratory distress before and after therapy at T1 ( $9.77 \pm 6.12$  vs.  $20.11 \pm 6.4$ ) decreased post-operatively in a statistically significant way ( $p < 0.000001$ ). Nasal respiratory distress before and after treatment at T2 ( $3.69 \pm 2.8$  vs.  $16.17 \pm 5.51$ ) decreased post-operatively in a statistically significant way ( $p < 0.000001$ ). No differences were found between group A and B at T0 ( $20.65 \pm 10.79$  vs.  $25 \pm 7.51$ ) ( $p > 0.000001$ ). The results are summarized in Figure 1.

### Endoscopic Nasal Score

The reduction of the mucosal edema and nasal secretion has been statistically significant in the Group A (1.71 vs. 4 in T1 and 1 vs. 2.48 in T2) (Figure 2).

### Microscopical Evaluation of Nasal Cytosmears (Basal Histology)

The quick MGG staining, an easy to perform basal staining to evaluate the inflammatory pattern, showed a cellular pattern characterized by neutrophils and monocytes, with rare goblet cells and mucus filaments. Eosinophils and mast cells were found absent. No biofilm (bacteria) was ob-

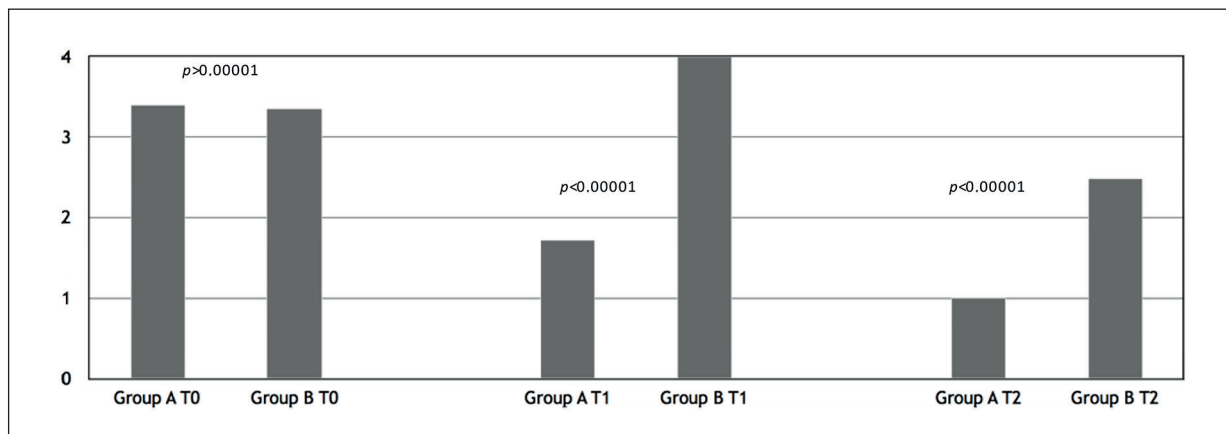


**Figure 1.** Snout evaluation in group A and B at T0, T1 and T2. Nasal respiratory distress before and after therapy at T1 and at T2 decreased post-operatively.

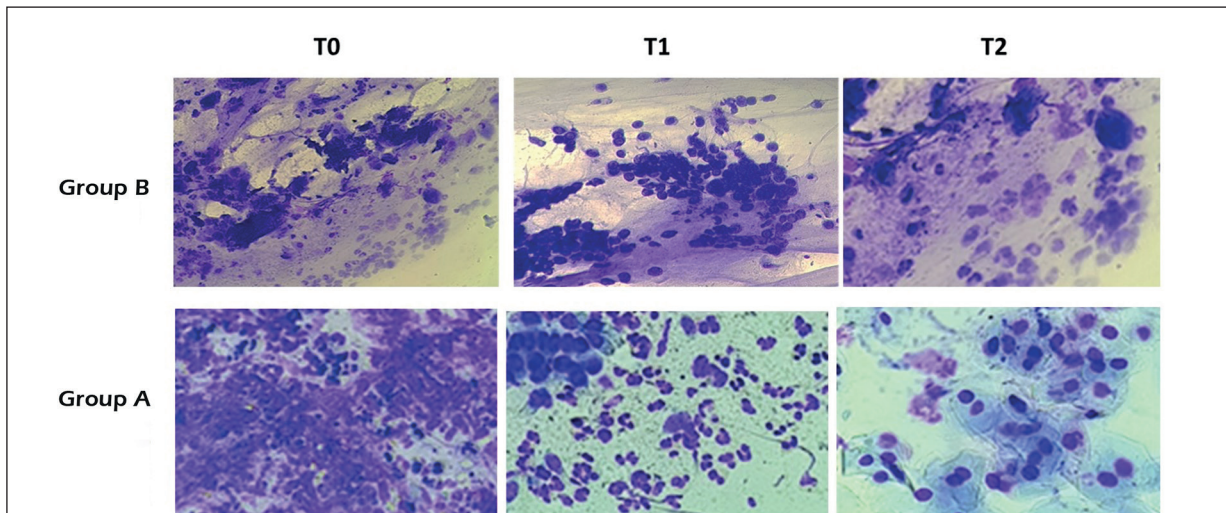
served. No metaplasia or hyperplasia phenomena were observed if analyzing the differentiated epithelial counterpart (goblet cells). The presence of mucus filaments (40%) was observed at T0. The microscopical comparison between nasal scraping from both groups is shown in Figure 3 with representative acquisitions for Group B (saline irrigation) and Group A (Trans-Resveratrol/Carboxymethylated (1.3/1.6)- $\beta$ -d-Glucan) treatments. A similar inflammatory reaction was observed at T0. By contrary, a different cytological appearance occurred at T1 and more evident at T2, if comparing both treatments. The increased number of neutrophils (polymorphonucleate cells with clear brown cytoplasm appearance) was observed at T1 and T2 with respect to T0. A slight cell reduction was

observed at T2 with respect to T1. Of interest, this decreased pattern is more evident in nasal scraping from Group A (Trans-Resveratrol/Carboxymethylated (1.3/1.6)- $\beta$ -d-Glucan treated) with respect to Group B (saline-treated patients). The appearance of epithelial cells at T2 of Group A [Trans-Resveratrol/Carboxymethylated (1.3/1.6)- $\beta$ -d-Glucan treated] is consistent with the reduction of inflammatory cells. In addition, the number of neutrophils appears higher in nasal scraping from Group A [Trans-Resveratrol/Carboxymethylated (1.3/1.6)- $\beta$ -d-Glucan treated] as compared to Group B (saline-treated) at T1 and T2.

The total number of goblet cells, responsible for the homeostasis of mucins, appeared in the normal range, although an increase in muc5AC-



**Figure 2.** Endoscopic Nasal Score The reduction of the mucosal edema and nasal secretion has been statistically significant in the Group A.



**Figure 3.** Microscopical Evaluation of Nasal Cytospins showed a cellular pattern characterized by neutrophils and monocytes, with rare goblet cells and mucus filaments.

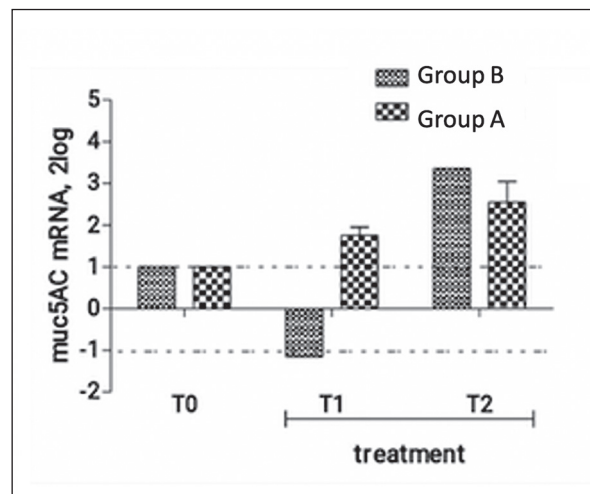
mRNA expression was observed after Trans-Resveratrol/Carboxymethylated (1.3/1.6)- $\beta$ -d-Glucan topical treatment (T1 and T2), resulting in a stabilization of nasal epithelium (Figure 4).

### Discussion

The aim of this study is to assess whether Trans-Resveratrol/Carboxymethylated (1.3/1.6)- $\beta$ -d-Glucan nasal spray can be useful to relieve nasal discomfort after FESS and to reduce time to recovery from surgery. To our knowledge, this study is the first that investigates the role of Trans-Resveratrol/Carboxymethylated (1.3/1.6)- $\beta$ -d-Glucan nasal spray after FESS. All patients well tolerated the treatment and no one dropped out of the study. Regarding Snot 20 questionnaire analysis, Group A and Group B showed no differences at T0. It is due to the fact that both groups had received saline solution irrigation as treatment. So that finding was expected. Analyzing data at T1 and T2 we found a significant difference in Snot evaluation within the two groups. Patients of Group A referred a reduction of discomfort after surgery comparing to those of the group B. This finding is supported by the endoscopic evaluation that showed a better score in Group A patients.

Overall, this pilot study sustains the potential ability of Trans-Resveratrol/Carboxymethylated (1.3/1.6)- $\beta$ -d-Glucan nasal spray to contribute to the recovery post FESS by means of a recruitment of neutrophils. With respect to neutrophils,

it has been recently hypothesized that in an inflammatory state, neutrophils might participate with a recovery of tissue homeostasis. Neutrophils are short-living cells exerting protective function against bacteria/fungi driven infections and scavenger activity for external/noxious substances and the release of mediators, including



**Figure 4.** muc5AC transcript expression. Relative real time PCR carried out in parallel on total RNA samples extracted from both groups (b and a). Note the increased expression on muc5AC mRNA at T2 for both groups. An increase was also observed at T1 specifically for group a. REST analysis on Cq values produced by amplification carried out in Illumina platform. T0 is referred to 1, as relative analysis was carried out, according to a standard procedure. Data are 2log expression. Bars are provided with standard deviation.

growth factors and angiogenic molecules with clear effects resolution of inflammation. Therefore, it might be possible that *via* the regulation of neutrophils, Resveratrol spray, thanks to its antioxidant effect<sup>16</sup>, may have a role in the deregulation of inflammation allowing a physiological recovery of nasal epithelial mucosa. The respiratory epithelium is lined by mucus, a gel consisting of water, ions, proteins, and macromolecules. The major macromolecular components of mucus are the mucin glycoproteins, which are critical for the airway's local defense. In our research, the evaluation of mucin proteins leads us to hypothesize the ability of Trans-Resveratrol/Carboxymethylated (1.3/1.6)- $\beta$ -d-Glucan nasal spray speeding up the healing of mucosa, restoring mucociliary homeostasis.

### Conclusions

This study demonstrates a significant reduction of the post-operative discomfort after surgery in patients in which Trans-Resveratrol/Carboxymethylated (1.3/1.6)- $\beta$ -d-Glucan nasal spray were administrated, compared to those who were treated with saline solution.

Moreover, we can assert that in patients treated with Trans-Resveratrol/Carboxymethylated (Group A), it appears less evident the presence of edema, nasal congestion, and crusts resulting in a quick recovery.

Additional investigations are necessary to confirm our encouraging results.

### Conflict of Interest

The Authors declare that they have no conflict of interests.

### References

- 1) FREMONT L. Biological effects of resveratrol. *Life Sci* 2000; 66: 663-673.
- 2) JEANDET P, BESSIS R, GAUTHERON B. The production of resveratrol (3,5,4'-trihydroxystilbene) by grape berries in different developmental stages. *Am J Enol Vitic* 1991; 42: 41.
- 3) WU JM, WANG ZR, HSIEH TC, BRUDER JL, ZOU JG, HUANG YZ. Mechanism of cardioprotection by resveratrol, a phenolic antioxidant present in red wine. *Int J Mol Med* 2001; 8: 3-17.
- 4) SUN AY, SIMONYI A, SUN GY. The "French paradox" and beyond: neuroprotective effects of polyphenols. *Free Radic Biol Med* 2002; 32: 314-308.
- 5) JANG M, CAI L, UDEANI GO, SLOWING KV, THOMAS CF, BEECHER CW, FONG HH, FARNSWORTH NR, KINGHORN AD, MEHTA RG, MOON RC, PEZZUTO JM. Cancer chemopreventive activity of resveratrol, a natural product derived from grapes. *Science* 1997; 275: 218-220.
- 6) MASTROMARINO P, CAPOBIANCO D, CANNATA F, NARDIS C, MATTIA E, DE LEO A, RESTIGNOLI R, FRANCIOSO A, MOSCA L. Resveratrol inhibits rhinovirus replication and expression of inflammatory mediators in nasal epithelia. *Antiviral Res* 2015; 123: 15-21.
- 7) GAO X, XU XY, JANAKIRAMAN N, CHAPMAN RA, GAUTAM SC. Immunomodulatory activity of resveratrol: suppression of lym-phocyte proliferation, development of cell-mediated cytotoxicity, and cytokine production. *Biochem Pharmacol* 2001; 62: 1299-1308.
- 8) ALEXANDER NS, HATCH N, ZHANG S, SKINNER D, FORTENBERRY J, SORSCHER EJ, WOODWORTH BA. Resveratrol has salutary effects on mucociliary transport and inflammation in sinonasal epithelium. *Laryngoscope* 2011; 121: 1313-1319.
- 9) SALVINELLI F, FRARI V, ROCCO ML, D'ERAMO A, SALVINELLI E, SALVINELLI B, ALOE L. High-pressure physiological saline isotonic solution administration enhances brain NGF and NGF-receptors expression. *Eur Rev Med Pharmacol Sci* 2015; 19: 3822-3832.
- 10) SALVINELLI F, FRARI V, ROCCO ML, ROSSO P, ALOE L. Enhanced presence of NGF and mast cells number in nasal cavity after autologous stimulation: relation with sensorineural hearing deficit. *Eur Rev Med Pharmacol Sci* 2015; 19: 381-391.
- 11) FRANCIOSO A, MASTROMARINO P, MASCI A, D'ERME M, MOSCA L. CHEMISTRY, STABILITY AND BIOAVAILABILITY OF RESVERATROL. *Med Chem* 2014; 10: 237-245.
- 12) FRANCIOSO A, MASTROMARINO P, RESTIGNOLI R, BOFFI A, D'ERME M, MOSCA L. Improved stability of trans-resveratrol in aqueous solutions by carboxymethylated (1.3/1.6)- $\beta$ -d-glucan. *J Agric Food Chem* 2014; 62: 1520-1525.
- 13) FREEMAN SR, SIVAYOHAM ES, JEPSON K, DE CARPENTIER J. A preliminary randomised controlled trial evaluating the efficacy of saline douching following endoscopic sinus surgery. *Clin Otolaryngol* 2008; 33: 462-465.
- 14) LOW TH, WOODS CM, ULLAH S, CARNEY S. A double-blind randomized controlled trial of normal saline, lactate Ringer's and hypertonic saline nasal irrigation solution after endoscopic sinus surgery. *Am J Rhinol Allergy* 2014; 28: 225-231.
- 15) GELARDI M, GUGLIELMI AV, DE CANDIA N, MAFFEZZONI E, BERARDI P, QUARANTA N. Effect of sodium hyaluronate on mucociliary clearance after functional endoscopic sinus surgery. *Eur Ann Allergy Clin Immunol* 2013; 45: 103-108.
- 16) YANG Y, WU ZZ, CHENG YL, LIN W, QU C. Resveratrol protects against oxidative damage of retinal pigment epithelium cells by modulating SOD/MDA activity and activating Bcl-2 expression. *Eur Rev Med Pharmacol Sci* 2019; 23: 378-388.